

# **DEGENERATIVE DISC DISEASE OF THE LUMBAR SPINE WITH SPONDYLOLISTHESIS TREATED WITH COX® DECOMPRESSION ADJUSTING**

**BY  
TED SICILIANO, DC**

**This case was a very unique and challenging one in that this patient not only had the common clinical findings of lumbar spine degenerative disc disease, i.e. bulging discs, spinal stenosis, thickening of the ligamentum flavum, but also had two spinal levels (L4-L5 & L5-S1) with spondylolisthesis with one level (L5-S1) having bilateral spondylolysis.**

## **CASE HISTORY:**

**On June 20, 2007, a female patient presented to me with a chief complaint of low back pain which radiated into the buttocks. This patient had suffered from this condition for over one year and was unsure as to how this condition began. The patient had received medical care, chiropractic treatment, physical therapy and 3 lumbar spine epidural injections which were not helpful in resolving this condition. This patient was very concerned as all prior treatments received to date had been ineffective in improving this condition. This low back condition severely limited the patient's activities of daily living and she was worried about her physical capabilities for the future. Upon the referral of a friend, this patient presented to me for the evaluation and treatment of her low back condition with Cox® Decompression Adjusting.**

## **HEALTH HISTORY:**

**This patient has a past health history of diverticulitis, low back pain with sciatica, surgery to remove her left kidney in 1979 and now is prone to kidney stones, underwent a cholecystectomy in 1981 and complains of leg cramps upon walking. This patient is allergic to penicillin and shellfish.**

## **INITIAL COMPLAINTS:**

**Initially, this patient complained of low back pain which radiated to the buttock described as sharp, dull, achy which began gradually and has been progressive in intensity. The patient has been experiencing this pain for over one year. The patient related that the pain worsened upon standing, bending, lifting, sleeping and lying down while sitting and light exercise would sometimes give mild relief. The patient rated this pain at an 8 (10 being worse 1 being least) and frequent (51% to 75% of the day). The patient's condition somewhat improves with sitting and sometimes after doing water aerobics or walking. The patient has also been experiencing anxiety and pain at night while trying to sleep.**

## **PHYSICAL EXAMINATION:**

The patient is a 68 year old female, who is 5'4'' tall and weighting 151 pounds. The patient was observed to have a normal gait but was unsteady getting on and off the adjusting table. Peripheral pulses of the lower extremities were equal bilaterally. Palpation for muscle spasms, pain and tenderness in the lumbar spine and buttock areas revealed tenderness at the left lumbar para-spinal musculature at the L2 through the S1 levels and at the left retrotrochanteric (GIO) area.

## **SPINAL RANGES OF MOTION:**

Lumbar spine ranges of motion were measured to be 30 degrees with pain in flexion, 18 degrees with pain in extension, 15 degrees with pain in right lateral bending and 15 degrees with pain in left lateral bending.

## **ORTHOPEDIC EXAMINATION:**

Minor's sign was absent. Bechterew's was positive for left leg. Valsalva and Bechterew's/Valsalva, Kemp's, Spinal Tilt, Neri Bow, Lewins were all negative. SLR, Braggard's, Medial Hip Rotation were positive for left leg but negative for the right leg. Lindner's and Patrick's test were both negative, bilaterally. Yeoman's, Ely's, Nachlas's were positive for the left leg and negative for the right leg. Prone Lumbar Flexion was positive. Popliteal fossa tenderness was not present in either leg.

## **MUSCLE STRENGTH EXAMINATION:**

Dorsi-flexion, Plantar-flexion, Hallux flexion/extension, Foot eversion, Gluteus Maximus, Biceps Femoris and Quadriceps were noted to 5 of 5 bilaterally.

## **NEUROLOGICAL EXAMINATION:**

Patellar and Achilles deep tendon reflexes were a +2, bilaterally with Babinski's being absent, bilaterally. Light touch sensation was noted to be within normal limits in the lower extremities, bilaterally.

## **LUMBAR SPINE MRI IMAGING:**

MRI of the lumbar spine dated 9-19-2006 revealed:

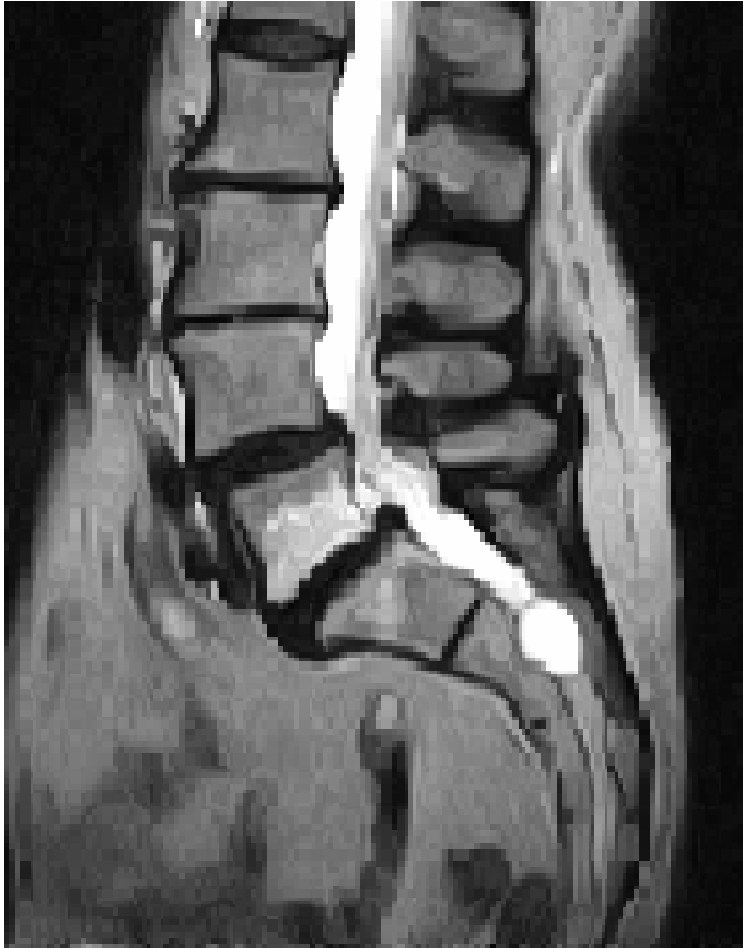Advanced L2-3 and L3-4 disc degenerative changes on sagittal image.

L2-L3 and L3-L4 show spondylitic annular bulging with mild central and left neural foraminal narrowing and mild to moderate right neural foraminal narrowing. The L4-L5 level shows annular bulging with facet and ligamentous hypertrophy with mild to moderate central and bilateral neural foraminal

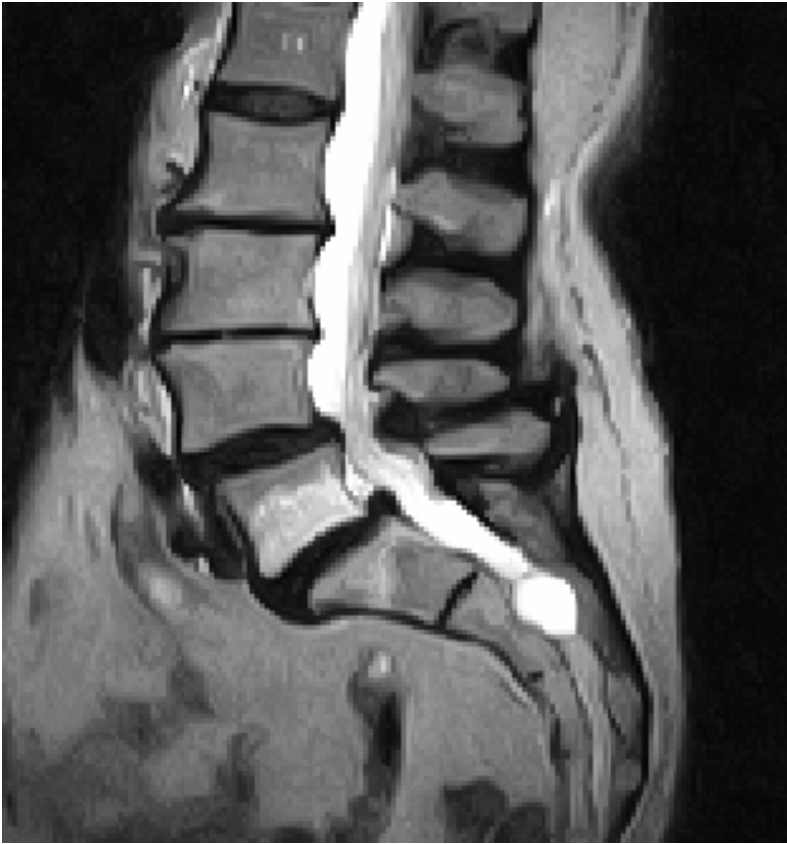narrowing. The L5-S1 level shows prominent facet arthropathy. There is mild to moderate central and bilateral neural foraminal narrowing. Tarlov cyst formation is noted in the lower sacral segments.

**IMPRESSION:**

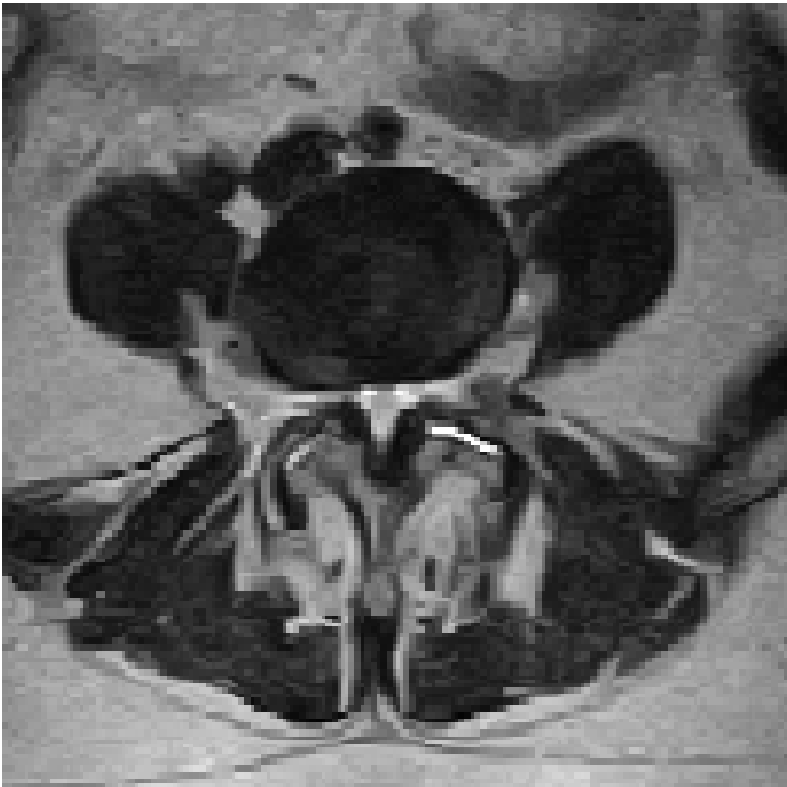Degenerative spondylolisthesis at the L5 and L4 levels due to degenerative disc and facet disease. Advanced degenerative disc disease at the L2 and L3 levels of the lumbar spine.



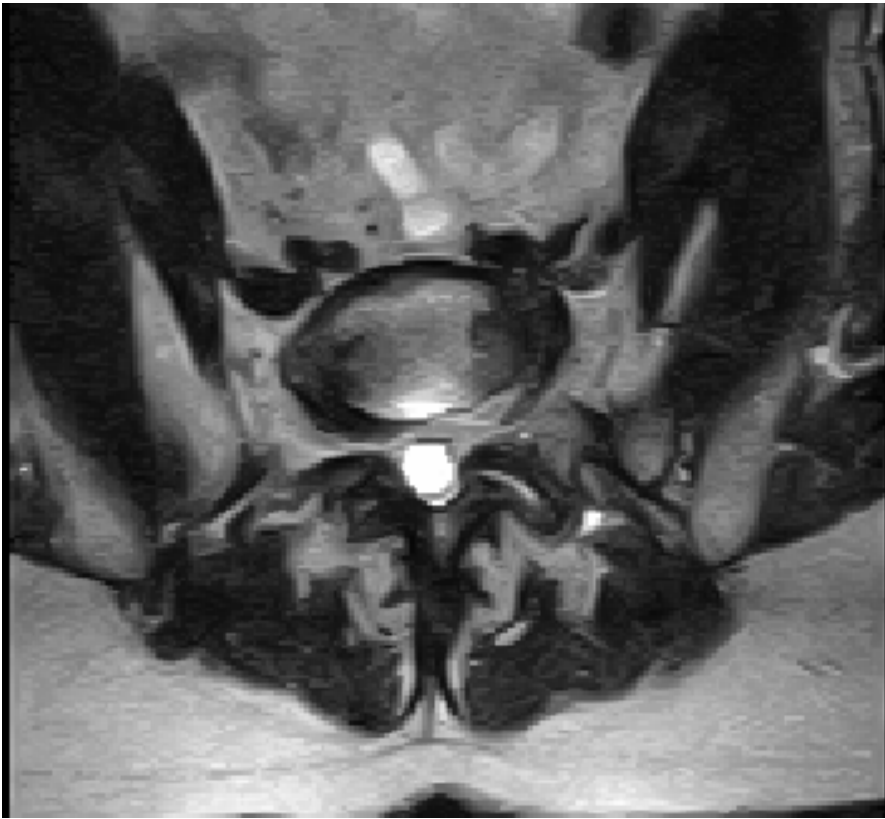
**Sagittal view of the lumbar spine. Figure 1.**



**Sagittal view of the Lumbar spine. Figure 2.**



**Axial view of the L4-L5 spinal segment. Figure 3.**



**Axial view of L5-S1 level. Figure 4.**

**TREATMENT PLAN:**

**This patient was given a treatment plan consisting of Cox® Decompression Adjusting, electrical muscle stimulation and a home stretching program. This treatment plan was to be administered three times per week for a four week period with an anticipated 50% subjective and objective clinical improvement at the end of this initial plan. Glucosamine sulfate and Chondroitin Sulfate were also recommended; however, this patient is allergic to shellfish therefore supplement therapy was not utilized. During the first treatment session, the patient was tolerance tested and protocol 1 was instituted. Since the patient was unable to lay prone for any time with having pain, electrical muscle stimulation was administered while sitting upon completion of decompression adjusting. Additionally, the patient was continually instructed in life style modification in order to increase her activities of daily living, i.e. bending, lifting, twisting and was given a home stretching program with a goal of resuming aqua aerobics classes if possible.**

**CONCLUSION:**

**This patient tolerated Cox® Decompression Adjusting very well and started to experience slight reduction of her low back pain after four treatments. As this treatment plan progressed the patient did experience exacerbations of her condition however these episodes usually occurred when the patient worked on her lawn**

**picking weeds or performing some other type of extreme activities. After receiving twelve treatments, the patient rated her pain as a 1 or 2 of 10. The patient had increased lumbar mobility and flexibility with a reduction in her positive spinal orthopedic examination. At this juncture, the treatment frequency was reduced and after receiving an additional eleven treatments the patient elected to receive monthly supportive chiropractic treatment. A recent re-examination revealed the patient's pain level was rated 0 to 1; ranges of motion of the lumbar spine were within normal limits without pain and a lumbar spine orthopedic examination was completely negative. This patient has had a significant increase in her activities of daily living and has renewed her membership to the local health club where she takes aqua aerobic classes. Lastly, this patient is a 68 year old widow who lives alone. The increase in her activities of daily living enables her to care for herself and maintain a very good quality of life.**

**Respectfully submitted,**

**Ted Siciliano, DC**

**submitted 9/08**

**published at [www.coxtechnic.com/casereports.asp](http://www.coxtechnic.com/casereports.asp) on 10/16/08**